

Effectiveness of Distal Radial Locking Plate Fixation in Managing Unstable Distal Radial Fracture

S. Ripon Kumar Ghosh¹, Dr. Nripen Kumar Kundu², Shahidul Islam³, Dr. Saikat Ghosh⁴,
Dr. Prianka Ghosh⁵, Dr. Md Milton Morshed⁶

¹Assistant Professor, Department of Orthopaedics & Traumatology, Ad-din Women's Medical College Hospital, Dhaka, Bangladesh.

²Assistant Professor, Department of Orthopaedics, Popular Medical college hospital, Dhanmondi, Bangladesh.

³Professor & Head, Department of Orthopedics and Spine Surgery, Addin Women's Medical College Hospital, Dhaka, Bangladesh.

⁴Registrar, Department of Orthopaedics Surgery, Chattogram Medical College Hospital, Chattogram, Bangladesh.

⁵Internee doctor, Mugda Medical College Hospital, Dhaka, Bangladesh.

⁶Consultant, Department of Orthopaedics Surgery, CRP, Dhaka, Bangladesh.

***Corresponding Author:** S. Ripon Kumar Ghosh, Assistant Professor, Department of Orthopaedics & Traumatology, Ad-din Women's Medical College Hospital, Dhaka, Bangladesh

Abstract:

Background: Unstable distal radial fractures pose a significant clinical challenge due to the complexity of their management and the potential for long-term functional impairment. Traditional treatment approaches have shown limitations in achieving optimal stabilization and restoration of wrist function. The emergence of distal radial locking plate fixation presents a promising solution, offering improved stability and reduced rates of complication.

Aim of the Study: This study aimed to assess the effectiveness of distal radial locking plate fixation as a management strategy for unstable distal radial fractures.

Methods: This quasi-experimental study was conducted in the Department of Orthopedics and Traumatology, Chattogram Medical College Hospital, Chattogram, Bangladesh, spanning from June 2017 to July 2019. A total of 25 patients diagnosed with unstable distal radial fractures who underwent distal radial locking plate fixation were enrolled as participants in this study.

Results: In this study, participants had a mean operative time of 92.80 ± 21.70 minutes, with the majority (80%) undergoing procedures lasting between 80 to 120 minutes. Analysis of complications revealed that 32% experienced soft tissue infections, and an equal number encountered delayed union of fractures. Wrist stiffness, affecting 56% of participants, was a common issue. Radiological union spanned 12 to 16 weeks for 71% of cases, while 29% required 22 to 26 weeks, with a mean \pm SD time of 16.67 ± 5.26 weeks. Using the Quick DASH Score system, outcomes were favorable, with 52% achieving a 'good' outcome, 35% an 'excellent' outcome, and 13% attaining 'fair' results.

Conclusion: The utilization of distal radial locking plate fixation proves to be a valuable management strategy for addressing unstable distal radial fractures. This study revealed favorable trends in operative duration and postoperative outcomes. Radiological union exhibited variability, showcasing the adaptability of this technique. These findings collectively support the effectiveness of distal radial locking plate fixation in effectively managing unstable distal radial fractures.

Keywords: Effectiveness, Distal radial locking plate fixation, Unstable, Radial fracture, Bone

1. INTRODUCTION

Fractures occurring in the distal radius are commonplace and constitute approximately 17.5% of all adult fractures [1]. Although various incidences have been reported, interpretation is complicated due to differences in population age and data recording

methodologies. Recent data from Edinburgh (2010-2011) and Finland (2008) indicate similar incidences in each country, approximately 23.6 and 25.8 per 10,000 per year respectively, for adult distal radius fractures [2]. These fractures are well-documented in the literature [3,4] and their increasing prevalence is attributed to an

aging population and increased outdoor activities [5]. The AO classification, now AO/OTA, is the prevailing system for categorizing distal radius fractures, dividing them into three types (A-extra-articular, B-partial articular, and C-complete articular), further categorized into 9 main groups and 27 subtypes based on comminution and displacement direction [6]. Various treatment options exist for managing distal radius fractures, encompassing non-operative approaches, external fixation, and internal fixation. Notably, a prospective study by Pradhan et al. [7] highlighted the advantages of volar locking plates over external fixation in the early postoperative period, though these advantages waned over time, suggesting that each fixation technique should be chosen on an individual basis by surgeons. In a prospective randomized study conducted by Shukla et al. (2014) [8], 68 patients were treated with external fixation and 42 with volar locking plates. At the one-year follow-up, external fixation demonstrated superior outcomes in terms of range of motion, grip strength, and final results. However, no significant differences were observed in pain and activity between the two groups. Additionally, patients under 50 years of age treated with external fixation exhibited excellent results at the one-year mark. Wilcke, Abbaszadegan, and Adolphson's 2011 [9] study involved 63 patients under 70 years old with unstable extra-articular or non-comminuted intra-articular dorsally displaced distal radius fractures. These patients were randomized into volar-locked plating or bridging external fixation groups. At 3 and 6 months, the volar plate group displayed better DASH and PRWE scores, while grip strength and range of movement were superior. However, these differences diminished and became small by the 12-month assessment point. A meta-analysis done by Cui et al. (2011) [10], suggested that the final results were significant and there was some evidence supporting the use of open reduction and internal fixation. The objective of this current study was to assess the effectiveness of distal radial locking plate fixation as a management strategy for unstable distal radial fractures.

2. METHODOLOGY

This was a quasi-experimental study that was conducted in the Department of Orthopedics and Traumatology, Chattogram Medical College Hospital, Chattogram, Bangladesh, spanning from June 2017 to July 2019. A total of 25

patients diagnosed with unstable distal radial fractures who underwent distal radial locking plate fixation were enrolled as participants in this study. The sample selection employed a convenient purposive sampling technique. The protocol was approved by the ethical review committee, Chattogram Medical College Hospital, Chattogram, Bangladesh. Properly written consent was taken from all the participants before data collection. The whole intervention was conducted following the principles of human research specified in the Helsinki Declaration [11] and executed in compliance with currently applicable regulations and the provisions of the General Data Protection Regulation (GDPR) [12]. As per the inclusion criteria of this study, patients aged between 18 and 65 years with AO/OTA 2.3-B2 to C3 fractures fit for anesthesia with a fracture duration of less than 1 week. On the other hand, according to the exclusion criteria of this study, patients with open fractures of the distal radius, pathological fractures, polytrauma patients and patients unwilling to give written consent were excluded. In this study, the postoperative variables were postoperative pain, complications, time for radiological union and functional outcome. Functional outcomes were measured by the Quick DASH Score system [13]. A total of 5 follow-up assessments were conducted, with the final follow-up taking place at the 12-month mark. Data were analyzed using SPSS version 25.0. Categorical data were expressed as frequency and percentage and compared using the chi-square test, while quantitative data were presented as mean and standard deviation (SD) and compared using Student's t-test. Postoperative outcomes were evaluated using confidence intervals. A significance level of 0.05 was applied, with $p < 0.05$ indicating significance.

3. RESULT

In this study, within our participant pool ($n=25$), approximately one-third originated from the 46-55 years age bracket, followed by 20% each from the 18-25 and 26-35 age groups. The mean \pm SD age of the participants was 40.36 ± 11.87 years; males constituted 72% of the total, while females comprised 28%. Approximately 64% of our patients sustained injuries due to road traffic accidents (RTAs), accounting for about two-thirds of the cases. In the majority of the cases (64%), the right side was involved. Fracture type C1 was observed in over one-third of participants (36%), with type B3 following at 20%. The participants had a mean operative

time of 92.80 ± 21.70 minutes. Notably, the majority of participants (80%) underwent procedures lasting between 80 to 120 minutes. In analyzing the complications among the study participants, we observed that a total of 8 participants (32%) experienced soft tissue infections, while an equal number also encountered delayed union of fractures. Wrist stiffness, a common issue, affected 14 participants (56%). Within this study, a

significant proportion of cases (71%) required a span of 12 to 16 weeks for radiological union, while 29% of cases necessitated a timeframe of 22 to 26 weeks; the mean \pm SD needed time was 16.67 ± 5.26 weeks. Utilizing the Quick DASH Score system, our observations indicated that a 'good' outcome was evident in the majority of patients (52%), followed by 35% achieving an 'excellent' outcome and 13% attaining 'fair' results.

Table1. Distribution of participants as per age (N=25)

Age (Year)	n	%
18-25	5	20%
26-35	5	20%
36-45	4	16%
46-55	8	32%
56-65	3	12%

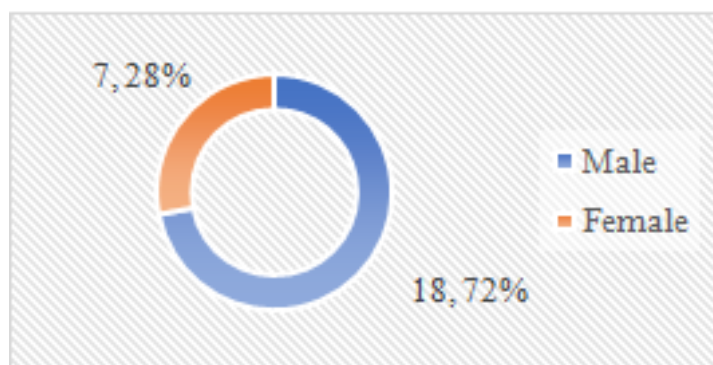


Figure1. Distribution of participants as per gender (N=25)

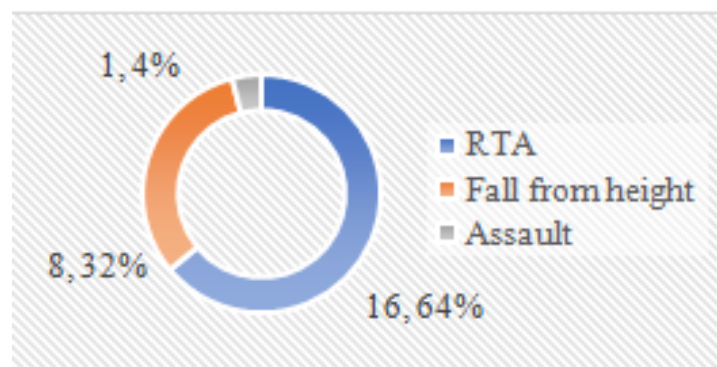


Figure2. Distribution of participants as per mechanism of injury (N=25)

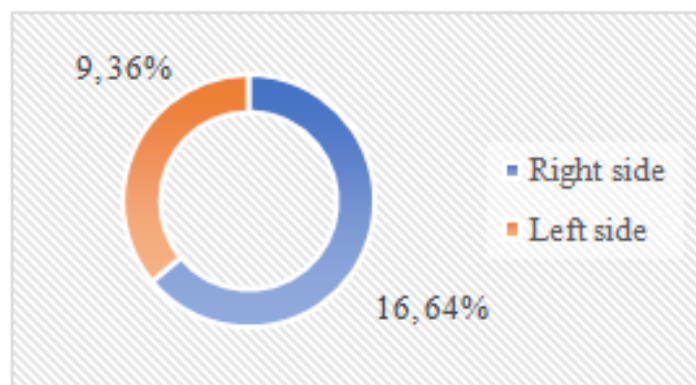


Figure3. Distribution of participants as per side involvement (N=25)

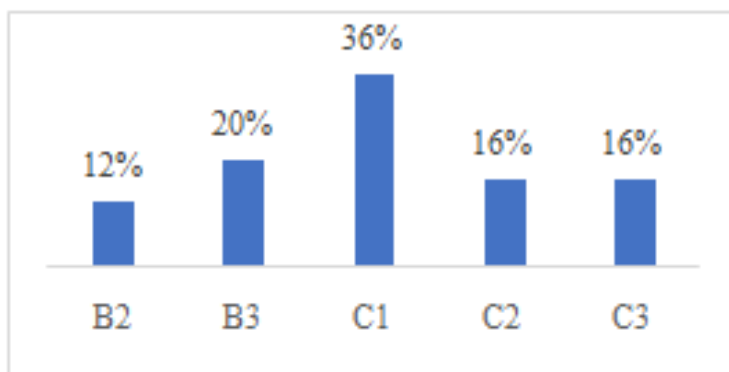


Figure4. Distribution of participants as per types of fracture (N=25)

Table2. Distribution of participants as per operative time (N=25)

Duration of operation	n	%
30-70 minutes	5	20%
80-120 minutes	20	80%
Mean ± SD (minutes)	92.80 ± 21.70	

Table3. Distribution of postoperative complications (N=25)

Complication	n	%
Soft tissue infection	8	32%
Delayed union	8	32%
Wrist stiffness	14	56%

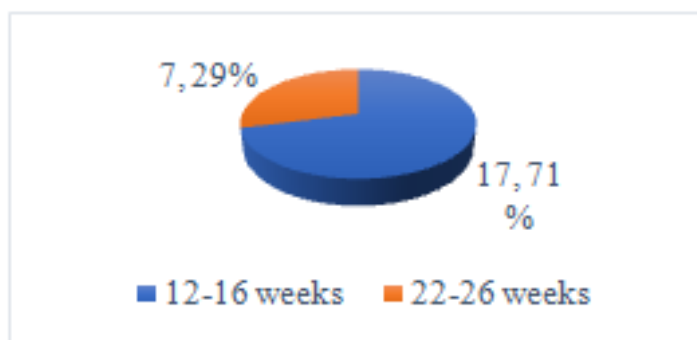


Figure5. Distribution of the patients according to the time taken for radiological union (n=24)

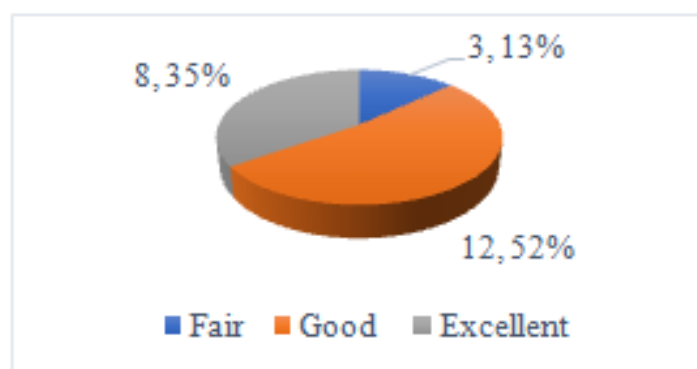


Figure6. Distribution of the functional outcome at the 12th month (n=23)

4. DISCUSSION

This study aimed to assess the effectiveness of distal radial locking plate fixation as a management strategy for unstable distal radial fractures. In this study, among our cohort of participants (n=25), around a third fell within the 46-55 years age range, with 20% each from

the 18-25 and 26-35 age categories. The participants' average age ± standard deviation was 40.36 ± 11.87 years. Among the total, males constituted 72%, while females made up 28%. These figures were compared favorably with another study conducted by Shukla et al. (2014) [8]. Another study conducted by Kundu

et al. (2017) [14] revealed average age was 42 years. In Pradhan et al. (2015) [7] study the male-female ratio was 11:15 in the volar locking plate group, comparable to our findings. In the majority of our cases (64%), the right side was involved. Another study by Nagnur et al. (2016) [15] reported that side involvement in that study in the LCP group 14:6 (R: L) and in EXFIX 9:11 (R: L). Our participants had a mean operative time of 92.80 ± 21.70 minutes. Notably, the majority of participants (80%) underwent procedures lasting between 80 to 120 minutes. Another study by Shukla et al. (2014) [8] corresponds with the present result, the mean operative time was 56.5 ± 2.7 min in the volar plate fixation group. In analyzing the complications among our study participants, we observed that a total of 8 participants (32%) experienced soft tissue infections, while an equal number also encountered delayed union of fractures. Wrist stiffness, a common issue, affected 14 participants (56%). In Ma et al. (2016) [16] study, in the plating group, post-operative nerve deficit was in 3, wound infection was in 6, pin-track infection was in 0, painful-retained hardware was in 1, tendon rupture was in 2, tendonitis was in 8, nonunion was in 2 and further surgery was in 7 of the cases. Within this study, a significant proportion of cases (71%) required a span of 12 to 16 weeks for radiological union, while 29% of cases necessitated a timeframe of 22 to 26 weeks; the mean \pm SD needed time was 16.67 ± 5.26 weeks. In Phandis et al. (2012) [17] study, the overall mean time to union was 8.4 weeks and in another study by Kundu et al. (2017) [14], the mean time to union was 8 weeks ranging from 6 to 12 weeks. Utilizing the Quick DASH Score system, our observations indicated that a 'good' outcome was evident in the majority of patients (52%), followed by 35% achieving an 'excellent' outcome and 13% attaining 'fair' results. In Nagnur et al. (2016) [15] study, in the LCP group, 45% were excellent, 45% were good, 10% were fair and 0% were poor and in the EXFIX group, 5% were excellent, 45% were good, 40% were fair and 10% were poor. In Phandis et al. (2012) [17], 133 patients (74%) had a good or excellent DASH score. All the findings of this current study may be helpful in further similar studies.

5. LIMITATION OF THE STUDY

This was a single-centered study with small-sized samples. Some patients could not come for follow up timely. Moreover, the study was conducted over a very short period. So, the

findings of this study may not reflect the exact scenario of the whole country.

6. CONCLUSION AND RECOMMENDATION

As per the findings of this current study, we can conclude that the utilization of distal radial locking plate fixation proves to be an effective management strategy for addressing unstable distal radial fractures. This study revealed favorable trends in operative duration and postoperative outcomes, along with the recognition of common complications such as soft tissue infections, delayed union of fractures, and wrist stiffness. Radiological union exhibited variability, showcasing the adaptability of this technique. These findings collectively support the efficacy of distal radial locking plate fixation in effectively managing unstable distal radial fractures, suggesting its potential as a promising approach in clinical practice. For getting more specific results, we would like to recommend conducting similar studies in several places with larger-sized samples.

REFERENCES

- [1] Court-Brown, C. M. and Caesar, B. (2006). Epidemiology of adult fractures: a review, *Injury*, 37(8): p. 691-7. doi: 10.1016/j.injury.2006.04.130.
- [2] Flinkkilä, T., et al. "Epidemiology and seasonal variation of distal radius fractures in Oulu, Finland." *Osteoporosis International* 22 (2011): 2307-2312.
- [3] Lichtman, D. M., Bindra, R. R., Boyer, M. I., Putnam, M. D. and Ring, D. (2010). Distal radius work group: The treatment of distal radius fractures, *J Am Acad Orthop Surg*, 18: p. 180-189.
- [4] Handoll, H. H., Huntley, J. S. and Madhok, R. (2007). External fixation versus conservative treatment for distal radial fractures in adults, *Cochrane Database Syst Rev*, 18(3): CD006194.
- [5] Jupiter, J. B., Ring, D. and Weitzel, P. P. (2002). Surgical treatment of re-displaced fractures of the distal radius in patients older than 60 years, *J Hand Surg Am*, 27: p. 714-23.
- [6] Marsh, J. L., Slongo, T. F., Agel, J., et al. (2007). Fracture and dislocation classification compendium - 2007: Orthopaedic Trauma Association classification, database and outcomes committee, *J Orthop Trauma*, 21: S1-S133.
- [7] Pradhan, R. L., Sharma, S., Pandey, B. K., Manandhar, R. R., Prasai, T., Lakhey, S. and Rijal, K. P. (2015). Comparison of volar locking plate and external fixation with K wire

- augmentation in unstable distal radius fractures, *Nepal Med Coll J*, 17(1-2): p. 67-72.
- [8] Shukla, R., Jain, R. K., Sharma, N. K. and Kumar, R. (2014). External fixation versus volar locking plate for displaced intraarticular distal radius fractures: a prospective randomized comparative study of the functional outcomes, *J Orthopaed Traumatol*, 15:265–270. DOI 10.1007/s10195-014-0317-8
- [9] Wilcke, M. K. T., Abbaszadegan, H. and Adolphson, P. Y. (2011). Wrist function recovers more rapidly after volar-locked plating than after external fixation but the outcomes are similar after 1 year, *Acta Orthopaedica*, 82: p. 76-81.
- [10] Cui, Z., Pan, J., Yu, B., Zhang, K. and Xiong, X. (2011). Internal versus external fixation for unstable distal radius fractures: an up-to-date meta-analysis, *International Orthopaedics (SICOT)*, 35: p. 1333–1341. DOI 10.1007/s00264-011-1300-0.
- [11] World Medical Association. (2001) . World Medical Association Declaration of Helsinki. Ethical principles for medical research involving human subjects. *Bulletin of the World Health Organization*, 79 (4) , 373 - 374. World Health Organization. <https://apps.who.int/iris/handle/10665/268312>.
- [12] Voigt, Paul, and Axel von dem Bussche. "Enforcement and fines under the GDPR." The EU General Data Protection Regulation (GDPR). Springer, Cham, 2017. 201-217.
- [13] Gummesson, C., Ward, M. M. and Atroshi, I. (2006). The shortened disabilities of the arm, shoulder and hand questionnaire (Quick DASH): validity and reliability based on responses within the full-length DASH, *BMC MusculoskeletalDisord*, 7: p. 44.
- [14] Kundu, A. K., Wale, N., Phuljhele, S., Ghritlahre, D. and Gurudatta, H. S. (2017). Intra articular distal radius fractures and volar plate fixation: a prospective study, *Int J Res Orthop*, 3: p. 589-94.
- [15] Nagnur, R. K., Patil, A. B., Angadi, V. and Palled, G. S. (2016). Locking compression plate fixation vs external fixator for distal radius fractures, *International Journal of Orthopaedics Sciences*, 2(3): p. 92-96.
- [16] Ma, C., Deng, Q., Pu, H., Cheng, X., Kan, Y., Yang, J., Yusufu, A. and Cao, L. (2016). External fixation is more suitable for intra-articular fractures of the distal radius in elderly patients, *Bone Research*, 4: p. 16017. doi:10.1038/boneres.2016.17.
- [17] Phadnis, J., Trompeter, A., Gallagher, K., Bradshaw, L., Elliott, D. S. and Newman, K. J. (2012). Mid-term functional outcome after the internal fixation of distal radius fractures, *Journal of Orthopaedic Surgery and Research*, 7:4.

Citation: S. Ripon Kumar Ghosh et al. *Effectiveness of Distal Radial Locking Plate Fixation in Managing Unstable Distal Radial Fracture*. *ARC Journal of Orthopedics*. 2023; 8(1):1-6. DOI: <https://doi.org/10.20431/2456-0588.0801001>

Copyright: © 2023 Authors. This is an open-access article distributed under the terms of the Creative Commons Attribution License, which permits unrestricted use, distribution, and reproduction in any medium, provided the original author and source are credited.