

## Findings on Imaging of Chest and Abdomen in Testicular Tumor Patients Treated in a Specialized Hospital in Bangladesh

Dr. Kazi Abdullah Arman<sup>1\*</sup>, Dr. Rajib Banik<sup>2</sup>, Dr. Rumana Afroz Majumdar<sup>3</sup>, Dr. Narita Khurshid<sup>4</sup>

<sup>1</sup>Junior Consultant, Medical Oncology, Department of Medicine, BIRDEM General Hospital, Dhaka, Bangladesh.

<sup>2</sup>Junior Consultant, Department of Thoracic Surgery, BIRDEM General Hospital, Dhaka, Bangladesh.

<sup>3</sup>Associate Consultant, Department of Radiation Oncology, Labaid Cancer Hospital and Super Specialty Centre, Dhaka, Bangladesh.

<sup>4</sup>Senior Specialist, Department of Medical Oncology, Evercare Hospital, Dhaka, Bangladesh.

Received: 07 November 2024 Accepted: 21 December 2024 Published: 27 December 2024

**\*Corresponding Author:** Dr. Kazi Abdullah Arman, Junior Consultant, Medical Oncology, Department of Medicine, BIRDEM General Hospital, Dhaka, Bangladesh.

### Abstract:

**Introduction:** Testicular germ cell tumors are one of the most curable solid neoplasms due to remarkable treatment advances that began in the late 1970s. Previously, testicular cancer accounted for 11% of cancer deaths in men between the ages of 25 and 34. Major factors contributing to the current five-year survival rate of over 95 percent include improved surgical and staging techniques of testicular tumors. This study decided to determine the findings on imaging of the chest and abdomen among patients with testicular tumors.

**Methods:** This was a cross-sectional study conducted in the Department of Medical Oncology of the National Institute of Cancer Research and Hospital (NICRH), Dhaka, Bangladesh during the period from July 2015 to June 2016. In this study, we included a total number of 52 patients who were admitted as newly diagnosed at the NICRH.

**Result:** The mean age of the patients was  $32 \pm 10.2$  years. Histopathological analysis showed that 96.15% of cases were germ cell tumors. Imaging findings from abdominal ultrasound (USG) or CT scans demonstrated that 44.23% of patients had normal results, while 27.92% exhibited regional lymph node (LN) metastasis, 25% had non-regional LN metastasis, and 3.85% showed abdominal organ metastasis. Chest imaging revealed that 75% of patients had normal findings, while 17.30% had lung metastasis and 7.69% displayed mediastinal and/or paratracheal lymph node involvement.

**Conclusion:** Imaging of the chest and abdomen is crucial for the diagnosis, treatment, and staging of patients with testicular tumors. A significant portion of patients had advanced disease at the time of admission, particularly those with non-seminomatous germ cell tumors.

**Keywords:** Ultrasonogram, X-ray, Histopathology, Testicles, Germ cell tumors

### 1. INTRODUCTION

Testicular germ cell tumors are one of the most curable solid neoplasms due to remarkable treatment advances in the late 1970s. Before that time, testicular cancer accounted for 11 percent of cancer deaths in men between the ages of 25 and 34, and the five-year survival rate was 64 percent. [1] Major factors contributing to the current five-year survival rate of over 95 percent include improved surgical and staging techniques, a better

understanding of the natural history of testicular tumors, the use of platinum-based combination chemotherapy, and the availability of highly sensitive serum tumor markers to detect minimal residual disease. [2,3] The causes are still not completely understood. Sometimes malignant germ cell tumors run in families, while the role of heredity is uncertain. [4] Apart from a history of undescended testis and infantile inguinal hernia, no risk factors have been identified with certainty.[5] The risk

that a tumor will develop in an undescended testicle is 20 to 40 times higher than in a testicle that descends normally. [6,7]

Tumor cells may spread through the lymphatic and circulatory systems. The first lymph node stations in the testes are the lumbar lymph nodes, which are located close to the spinal column at the level of L2 to L4. Through the thoracic duct, tumor cells can subsequently travel lymphogenously, arriving in the mediastinum and supraclavicular lymph nodes. Through vascular invasion in the testicle, hematogenic dispersion can reach the lungs directly or indirectly through the thoracic duct, which connects to the lumbar lymph nodes, cisterna chyli, and subclavian vein. [8]

The most common symptom of a testicular tumor is painless swelling in the testicle. A patient's attention is frequently drawn to the swelling by minor trauma. Other symptoms might be similar to testicular torsion, orchitis, or epididymitis. Some individuals have signs of distant metastases but no testicular complaints or abnormalities. Because they compress or restrict the ureter, retroperitoneal lymph node metastases might result in renal colic or back discomfort. Pleural discomfort, hemoptysis, and dyspnea can all result from lung metastases. In addition, gynaecomastia can form the first clinical symptom of a tumor that produces human chorionic gonadotrophin (hCG). [9] Early detection of the disease by recognizing signs and symptoms that appeared first will be beneficial for patients with testicular tumors as the prognosis differs with the stage of the disease.

The availability of tumor markers to aid medical professionals in the treatment of testicular germ cell tumors (GCTs) is one characteristic that sets them apart. Following an orchiectomy, testicular tumor marker levels are essential for determining the appropriate disease stage, evaluating the prognosis of the patient, selecting the optimal treatment plan, monitoring the disease's response to therapy, and early recurrence detection during post-therapy surveillance. The tumor markers include lactate dehydrogenase (LDH), human chorionic gonadotropin (hCG), and alpha-fetoprotein (AFP). [10]

There are many histologic variations of testicular tumors. Nearly all testis tumors are germ cell tumors (GCTs), which are categorized as either seminoma or

nonseminoma GCTs (NSGCTs) based on histology. NSGCTs are divided into four subtypes: choriocarcinoma, yolk sac tumor, embryonal carcinoma, and teratoma. Approximately 60% of GCTs contain more than one of these histologic patterns (ie, mixed GCTs).[11] The most frequent combination of tumor types is embryonal, yolk sac, and teratoma. [11]

In this study, we decided to determine the findings on imaging of the chest and abdomen among patients with testicular tumors.

## **2. METHODOLOGY & MATERIALS**

This was a cross-sectional study conducted in the Department of Medical Oncology of the National Institute of Cancer Research and Hospital (NICRH), Dhaka, Bangladesh during the period from July 2015 to June 2016. In this study, we included a total number of 52 suspected male patients with testicular tumors who were admitted as newly diagnosed at the NICRH.

These are the following criteria to be eligible for enrollment as our study participants: a) Patients aged more than 15 years; b) Patients diagnosed with testicular tumor by histopathology, sonology, or biochemistry; c) Patients who were willing to participate were included in the study And a) Patients with extragonadal germ cell tumor; b) Patients with a severe handicap or psychological condition; c) Patient having the second primary elsewhere in the body; d) Patients with any history of acute illness (e.g., renal or pancreatic diseases, ischemic heart disease, asthma, COPD, etc.) were excluded from our study.

**Data collection tools:** Informed written consent was taken from the patient. The relevant socio-demographic characteristics, clinical findings as well as physical examination were performed. Patients' histopathology was recorded. If no orchidectomy or histopathology then the patients were sent for orchidectomy and/or histopathology depending upon the indication. All other required data was collected by face-to-face interview, physical examination, laboratory investigations (Serum AFP, Serum HCG & Serum LDH), histopathological, ultrasonogram, and chest X-ray or CT scan of the chest and/or abdomen. The staging was done and recorded as well.

## Findings on Imaging of Chest and Abdomen in Testicular Tumor Patients Treated in a Specialized Hospital in Bangladesh

**Statistical Analysis:** All data were recorded systematically in preformed data collection form. Quantitative data was expressed as mean and standard deviation and qualitative data was expressed as frequency distribution and percentage. Statistical analysis was performed

by using SPSS (Statistical Package for Social Sciences) for Windows version 10. Ethical approval was taken from the ethical review committee of the National Institute of Cancer Research and Hospital (NICRH).

### 3. RESULTS

**Table1.** Distribution of patients according to age (N=52)

Age (Years)	Frequency	Percentage
16-20	7	13.46
21-25	6	11.54
26-30	14	26.92
31-35	9	17.31
36-40	6	11.54
41-45	3	5.77
46-50	5	9.62
51-55	0	0
≥56	2	3.85

Table 1 shows the age distribution of patients with testicular tumors which showed a maximum of 14 (13.46%) patients distributed in the 25-30 years age group, followed by 9 patients (17.31%) in the 31-35 years age group, 7 patients (13.46%) in the 16-20 years age

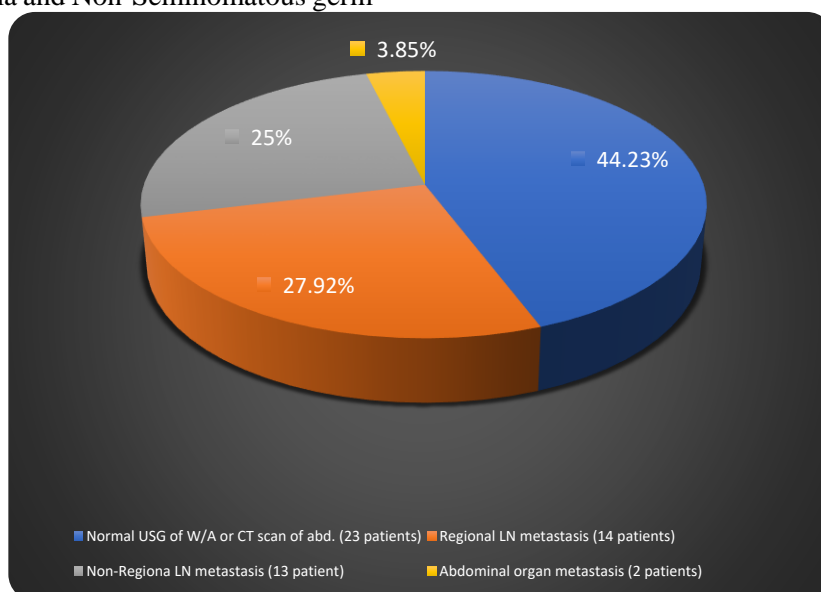
group, both the 21-25 and 36-40 years age groups had 6 patients (11.54%) and 46-50 years age group contains 5 patients (9.62%). The Mean age of our study patients was  $32 \pm 10.2$  years.

**Table2.** Frequency of different histopathology - germ cell tumor Vs other histopathology (N=52)

Histopathology	Frequency	Percentage
Germ cell tumor (Seminoma & NSGCT)	50	96.15%
Testicular Sarcoma	1	1.92%
Metastatic Mucinous Adenocarcinoma	1	1.92%

Table 2 shows the frequency of different histopathology - Germ cell tumor Vs other histopathology. It shows 50 patients (96.15%) are of Seminoma and Non-Seminomatous germ

cell histopathology, 1 (1.92%) is testicular sarcoma and another 1 (1.92%) is Metastatic Mucinous Adenocarcinoma.

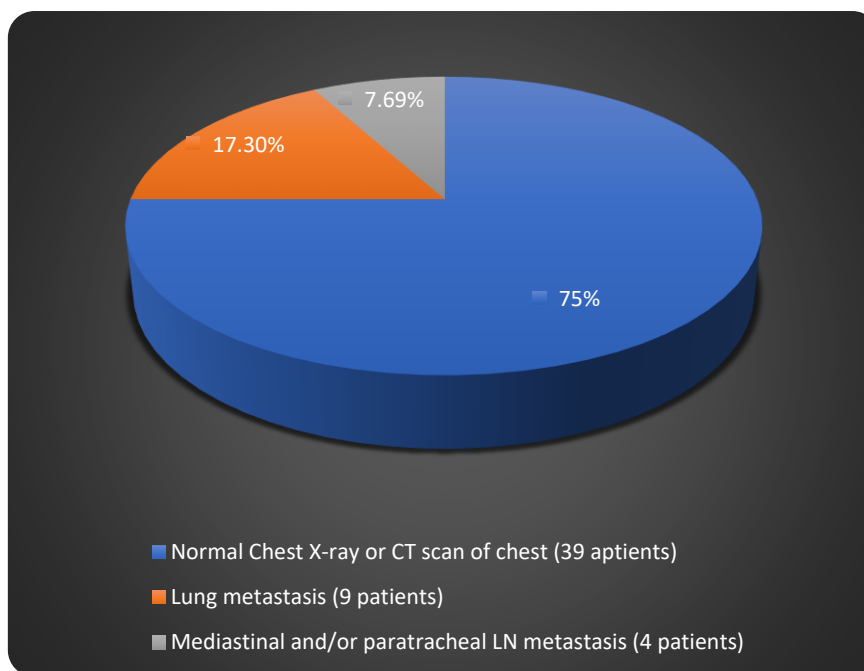


## Findings on Imaging of Chest and Abdomen in Testicular Tumor Patients Treated in a Specialized Hospital in Bangladesh

**Figure1.** Distribution of the study patients by the frequency of different findings of USG of W/A or CT scan of the abdomen.

The pie chart shows the distribution of findings observed through ultrasound (USG) of the whole abdomen or CT scans. The majority (44.23%) of patients showed no abnormalities, followed by 27.92% of patients who had

regional lymph node (LN) metastasis, 25% of patients presented with non-regional lymph node metastasis, and only 3.85% of patients displaying evidence of abdominal organ metastasis.



**Figure2.** Distribution of the study patients by the frequency of different findings of CXR P/A view or CT scan of the chest.

The pie chart displays the findings from chest imaging, including chest X-rays and CT scans, across the study patients. The majority (75%) of patients had normal imaging results, indicating no visible abnormalities in their lungs or chest

area. Followed by 17.30% of patients showed signs of lung metastasis, and 7.69% of patients exhibited mediastinal and/or paratracheal lymph node metastasis.

**Table3.** Frequency of the level of tumor markers (S1/S2/S3) among the patients with testicular germ cell tumors (N=50)

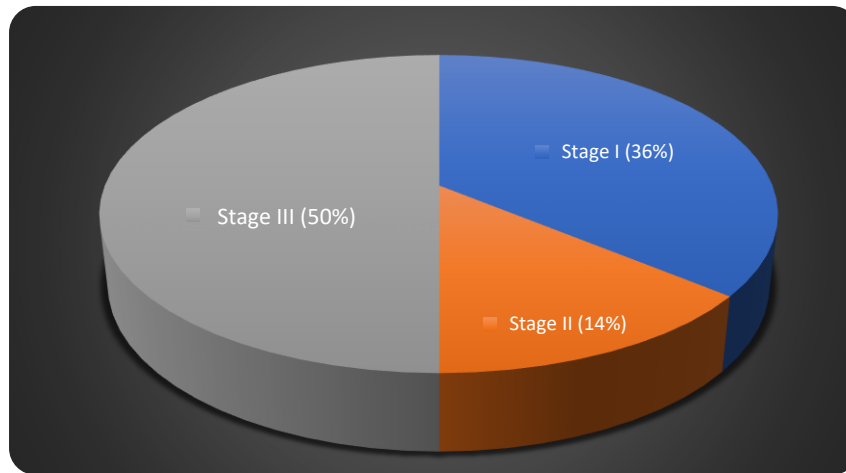
Level of Tumor markers	Frequency	Percentage
S1 = LDH <1.5×highest level of normal & βhCG < 5000mIU/ml & AFP <1000ng/ml	26	52
S2 = LDH 1.5 to 10×highest level of normal or βhCG 5000-50000mIU/ml or AFP 1000-10000ng/ml	23	46
S3 = LDH >10×highest level of normal or βhCG > 50000mIU/ml or AFP >10000ng/ml	1	2
Total	50	100

Table 3 shows the frequency of the level of tumor markers (S1/S2/S3) among the patients with testicular germ cell tumors which shows that 26 patients (52%) presented with S1 level of tumor marker, 23 patients (46%) presented with S2 level of tumor marker whereas only 1

patient (2%) presented with S3 level of tumor marker.

The pie chart shows the distribution of patients at different stages of the condition. Stage III is the most prevalent, occurring in 50% of cases and indicating considerable development in 50% of individuals. Followed by 36% of

patients were diagnosed with stage I, while Stage II is the least common, accounting for just 14%.



**Figure3.** Distribution of patients with germ cell tumors according to the stage during presentation

#### 4. DISCUSSION

Testicular tumor remains an uncommon malignancy accounting for 1–2% of all tumors in men but still it is the most common malignancy in young men. Some authors established that its incidence is increasing gradually. [12–15] Testicular cancers are very sensitive to chemotherapy and are potentially curable. Cure rates for good-risk disease are 90–95% and is now considered the model for the treatment of solid tumors. This is the most important reason for working with testicular tumors. It's a potentially curable tumor and the prognosis and treatment will be much better if a few issues can be modified positively. In this study, we observed that the most common age group is 26 to 30 years. This study established that the most common age for testicular tumors is 15 to 35. Laukka M et al found the median age was 33 years in their study. [16]

The study showed the most common histopathology of the testicular tumor is germ cell tumor (96.15%) which consists of both Seminoma and NSGCT. Only 1.92% is testicular sarcoma and 1.92% is metastatic mucinous adenocarcinoma.

USG of the whole abdomen and/or CT scan of the abdomen was normal at 44.23%. Regional lymph node metastasis was present in 27.92% whereas non-regional lymph node metastasis was present in 25% of patients. Only 3.85% of patients were presented with distant (abdominal organs) metastasis. It reflects the percentage of

the advanced stage of the disease. Regional lymph node metastasis falls in stage II disease whereas non-regional lymph nodes or distant metastasis falls in stage III. However, ultrasound is not recommended for use in distant staging of testicular cancer because it is vastly inferior to CT or MRI in assessing the presence and burden of disease.[17]

Chest X-ray P/A view and/or CT scan of chests was normal in 75% of patients. Lung metastasis was found in 17.30% and mediastinal and/or paratracheal lymph node metastasis was present in 7.69% of patients.

In a study by Harvey from the UK, only one out of 42, i.e., 2.4% of testicular cancer patients, relapsed with isolated intrathoracic disease without other indicator of relapse, and all 8 patients showed signs of disease in chest X-ray. [18] In a large study of 695 patients on surveillance for testicular cancer in Copenhagen, Denmark, only 4 out of 155 (2.6%) relapses were detected by chest X-ray. [19]

Although CT excels at identifying and determining the diameter of retroperitoneal lymph nodes, this modality cannot differentiate a lymph node that is infiltrated with malignant tissue from a lymph node that is benign. Therefore, malignant lymph nodes which are commonly described as having a diameter of 8–10 mm or more are identified using size criteria. Although it is heavily reliant on nodal size, the sensitivity of abdominopelvic CT is around 70–80% because of the high propensity for nodal

micrometastases in testicular cancer. [17, 20] Due to testicular cancer's propensity to spread to the mediastinal lymph nodes after it has entered the retroperitoneum, chest imaging is essential for early staging. A chest CT scan is the most sensitive test, but its specificity is lower and it has a larger percentage of false-positive findings. Past research assessed the sensitivity and specificity of chest CT in the initial staging of patients with seminoma and found that CT has a higher false-positive rate while maintaining the same sensitivity as radiography. Previous studies state chest radiography is found preferable in patients with seminoma and patients with NSGCT with normal abdominal imaging. [21]

Unfortunately, this study reveals that 50% of patients in Bangladesh present with stage III disease. 36% of patients present with stage I and 14% of patients present with stage II disease. If this scenario can be changed then the outcome of the disease will be improved and treatment failure can be reduced. Education and awareness among the young population are the key to reducing stage III disease prevalence.

#### **5. LIMITATIONS OF THE STUDY**

Our study was a single-center study. We took a small sample size due to our short study period. After evaluating those patients, we did not follow up with them for the long term and did not know other possible interference that may happen in the long term with these patients.

#### **6. CONCLUSION AND RECOMMENDATIONS**

In our study, we found that imaging of the chest and abdomen is crucial for the diagnosis, treatment, and staging of patients with testicular tumors. According to imaging data from this study conducted in a specialized hospital in Bangladesh, a significant portion of patients had advanced disease at the time of admission, particularly those with non-seminomatous germ cell tumors. While chest imaging often detected pulmonary metastases, abdomen imaging usually showed retroperitoneal lymph node involvement, underscoring the importance of a comprehensive radiographic evaluation at diagnosis.

So further study with a prospective and longitudinal study design including a larger sample size needs to be done to validate the findings of our study.

#### **REFERENCES**

- [1] Einhorn LH. Treatment of testicular cancer: a new and improved model. *J Clin Oncol.* 1990;8:1777.
- [2] Ries LA, Eisner MP, Kosary CL, et al. SEER Cancer Statistics Review, 1975-2001. National Cancer Institute, Bethesda, MD, 2004. Available at: [http://seer.cancer.gov/csr/1975\\_2007/index.html](http://seer.cancer.gov/csr/1975_2007/index.html). Accessed April 11, 2011.
- [3] Siegel R, Ward E, Brawley O, Jemal A. Cancer statistics, 2011: The impact of eliminating socioeconomic and racial disparities on premature cancer deaths. *CA Cancer J Clin.* 2011;61:212.
- [4] Wobbes Th, Hoekstra HJ, Sleijfer DTh, et al. Tumors of the testis in two brothers: a case report. *J Surg Oncol.* 1981;17:135-7.
- [5] Newling DWW, Jones WG, Forman D, Gallagher R, Moller H, Swerdlow AJ. Aetiology and epidemiology of testicular cancer: report of consensus group. In: Newling DWW, Jones WG, editors. *Prostate cancer and testicular cancer. Progress in clinical and biological research.* Vol 357. New York: Wiley-Liss; 1990. p. 245-53.
- [6] Wobbes Th, Schraffordt Koops H, Oldhoff J. The relation between testicular tumours, undescended testes, and inguinal hernias. *J Surg Oncol.* 1980;14:45-51.
- [7] Batata MA, Chu FCH, Hilaris BS, et al. Testicular cancer in cryptorchids. *CA.* 1982;49:1023-30.
- [8] Wobbes Th. Non-seminomatous germ cell tumours of the testis. Staging and treatment. Thesis, State University Groningen, 1981.
- [9] Einhorn LH, Richie JP, Shipley WU. Cancer of the testis. In: DeVita VT, Hellman S, Rosenberg SA, editors. *Cancer: principles & practice of oncology.* Philadelphia: J.B. Lippincott Company; 1989. p. 1126-51.
- [10] Gilbert SM, Daignault S, Weizer AZ, Wei JT, Hollenbeck BK. The use of tumor markers in testis cancer in the United States: a potential quality issue. *Urol Oncol.* 2008;26(2):153-7.
- [11] Richie J, Steele G. Neoplasms of the testis. In: Wein AJ, Kavoussi LR, Novick AC, Partin AW, editors. *Campbell-Walsh Urology.* Philadelphia, PA: Saunders; 2007. p. 907-8.
- [12] Toledano MB, Jarup L, Best N, Wakefield J, Elliot P. Spatial variation and temporal trends of testicular cancer in Great Britain. *Br J Cancer.* 2001;84:1482-73.
- [13] Gudbjartsson T, Magnusson K, Bergthorsson J, et al. A population-based analysis of increased incidence and improved survival of testicular cancer patients in Iceland. *Scand J Urol Nephrol.* 2003;37:292-8.

- [14] Huyghe E, Matsuda T, Thonneau P. Increasing incidence of testicular cancer worldwide: a review. *J Urol.* 2003;170:5–11.
- [15] McGlynn KA, Devesa SS, Sigurdson AJ, Brown LM, Tsao L, Tarone RE. Trends in the incidence of testicular germ cell tumors in the United States. *Cancer.* 2003;97:63–70.
- [16] Laukka M, Mannisto S, Beule A, Kouri M, Blomqvist C. Comparison between CT and MRI in detection of metastasis of the retroperitoneum in testicular germ cell tumors: a prospective trial. *Acta Oncol.* 2020;59(6):660-5.
- [17] Kreydin EI, Barrisford GW, Feldman AS, Preston MA. Testicular cancer: what the radiologist needs to know. *Am J Roentgenol.* 2013;200(6):1215-25.
- [18] Harvey ML, Geldart TR, Duell R, et al. Routine computerised tomographic scans of the thorax in surveillance of stage I testicular non-seminomatous germ-cell cancer—a necessary risk? *Ann Oncol.* 2002;13:237–42.
- [19] Daugaard G, Petersen PM, Rorth M. Surveillance in stage I testicular cancer. *Apmis.* 2003;111:76–83.
- [20] Leão R, Ahmad AE, Hamilton RJ. Testicular cancer biomarkers: a role for precision medicine in testicular cancer. *Clin Genitourin Cancer.* 2019;17(1):e176-83.
- [21] Corp IB. IBM SPSS statistics for windows, version 22.0. Armonk, NY: IBM Corp; 2013.